

Collagen crosslinking with riboflavin and ultraviolet-A light in keratoconus: Long-term results

Frederik Raiskup-Wolf, MD, Anne Hoyer, MD, Eberhard Spoerl, PhD, Lutz E. Pillunat, MD

PURPOSE: To prove the long-term dampening effect of riboflavin- and ultraviolet-A-induced collagen crosslinking on progressive keratoconus.

SETTING: Department of Ophthalmology, C.G. Carus University Hospital, Dresden, Germany.

METHODS: Four hundred eighty eyes of 272 patients with progressive keratoconus were included in this long-term retrospective study. The maximum follow-up was 6 years. At the first and all follow-up examinations, refraction, best corrected visual acuity (BCVA), corneal topography, corneal thickness, and intraocular pressure were recorded.

RESULTS: The analysis included 241 eyes with a minimum follow-up of 6 months. The steepening decreased significantly by 2.68 diopters (D) in the first year, 2.21 D in the second year, and 4.84 D in the third year. The BCVA improved significantly (≥ 1 line) in 53% of 142 eyes in the first year, 57% of 66 eyes in the second year, and 58% of 33 eyes in the first year or remained stable (no lines lost) in 20%, 24%, and 29%, respectively. Two patients had continuous progression of keratoconus and had repeat crosslinking procedures.

CONCLUSIONS: Despite the low number of patients with a follow-up longer than 3 years, results indicate long-term stabilization and improvement after collagen crosslinking. Thus, collagen crosslinking is an effective therapeutical option for progressive keratoconus.

J Cataract Refract Surg 2008; 34:796–801 © 2008 ASCRS and ESCRS

Keratoconus is a corneal degeneration characterized by bilateral conical protrusion and corneal thinning.¹ The average age of appearance of keratoconus is the second decade of life.² The course of the disease varies from slight irregular astigmatism to severe visual impairment due to increasing protrusion and subepithelial scarring. Because of the young age of the patients, keratoconus often has a significant negative effect on quality of life.³ Results of currently available treatment options are not encouraging because the treatments do

not stop the progression of keratoconus. Thus, because of its progressive nature, keratoconus was the most frequent reason for keratoplasty in the past 3 decades.⁴

Keratoconus leads to biomechanical alterations, and its specific cause is not known. The biomechanical characteristics of the cornea result from the collagen scaffold and collagen compound and their bonding with the collagen fibrils. The 3-dimensional configuration of the collagen lamella fundamentally codetermines the cornea's resistance. Biochemical and immunohistochemical studies of the matrix's proteoglycans show differences between normal and keratoconic corneas.^{5–8} Enzymatic alterations with an increased expression of lysosomal and proteolytic enzymes,^{6,9–11} decreased concentration of protease inhibitors,^{9,12} decreased thickness,⁶ and modified configuration of the stromal collagen lamella^{13–15} have been observed.

A photooxidative collagen crosslinking technique using riboflavin and ultraviolet-A (UVA) light was developed to counteract the progressive corneal thinning, and thus the progression, of keratoconus. With crosslinking, additional covalent binding between

Accepted for publication December 27, 2007.

From the Department of Ophthalmology, C.G. Carus University Hospital, Dresden, Germany.

No author has a financial or proprietary interest in any material or method mentioned.

Corresponding author: Frederik Raiskup-Wolf, MD, Department of Ophthalmology, C.G. Carus University Hospital, Dresden, Germany. E-mail: frederik.raiskup-wolf@uniklinikum-dresden.de.

collagen molecules can be achieved, which stabilizes the collagen scaffold and changes several tissue properties.¹⁶

An increase in corneal stiffness and enhanced resistance against proteolytic enzymes caused by the riboflavin and UVA light was shown in enucleated pig eyes.¹⁷⁻²⁰ The crosslinking effect is not distributed homogeneously over the corneal depth. The stiffening effect is concentrated in the anterior 200 to 300 μm of the cornea due to the high absorption of UV light in this area.²¹

In 1998, the first keratoconus patients had crosslinking. To date, 480 eyes of 272 patients have had the treatment at the Department of Ophthalmology, C.G. Carus University Hospital, Dresden, Germany.

PATIENTS AND METHODS

This longitudinal study with consecutive recruitment comprised patients with progressive keratoconus and a corneal thickness of at least 400 μm . All patients were older than 18 years. The institutional ethics committee approved the study, and all patients provided informed consent after receiving a detailed description of the nature of the treatment.

Progression indicating the necessity for treatment was based on an increase in maximum keratometry (K) of 1.00 diopter (D) in 1 year, patient reports of deteriorating visual acuity²² (excluding other possible non-cornea-related reasons for deterioration), or the need for new contact lens fitting more than once in 2 years.

Technique Background

Riboflavin (vitamin B2) has 2 important functions; it absorbs UV irradiation and acts as a photosensitizer for the generation of reactive oxygen species (singlet oxygen). In combination with UV light, riboflavin forms radicals that cause the crosslinking. When riboflavin penetrates the stroma sufficiently, it shields the deeper tissues such as the lens and retina. Ultraviolet-A light of 370 nm wavelength (riboflavin's absorption maximum) and 3 mW/cm^2 was used in this study. The 370 nm wavelength allows approximately 95% of UV light to be absorbed into the cornea; thus, there is no risk for damage to the lens and retina. Before treatment, the 3 mW/cm^2 irradiance was checked with a LaserMate-Q UVA meter (Laser 2000). Since 2006, the UV-X irradiation tool (Fa. Peschke) with 3 mW/cm^2 irradiance has been used in the Department of Ophthalmology.

Surgical Technique

The crosslinking was performed in the outpatient service of the Department of Ophthalmology. After topical anesthesia of proxymetacaine hydrochloride 0.5% eyedrops was administered, the epithelial tissue was removed in a 9.0 mm diameter area. This was to ensure that the riboflavin penetrated the stroma and that a high level of UVA absorption was achieved.

As a photosensitizer, 0.1% riboflavin solution was applied to the cornea 20 minutes before the irradiation to allow sufficient saturation of the stroma.²³ Next, an 8.0 mm diameter of central cornea was irradiated with UVA light with a wavelength of 370 nm and an irradiance of 3 mW/cm^2 . Two UVA

diodes with a 10-degree radiation divergency were used as the UVA radiation source. During the 30 minutes of irradiation, drops of riboflavin solution were applied to the cornea every 4 to 5 minutes to sustain the necessary concentration of the riboflavin and prevent desiccation of the cornea.

Postoperative Regimen

After crosslinking, antibiotic eye ointment (ofloxacin) and vitamin A eye ointment (VitA-POS) were applied. Analgesics were prescribed. The ointments were applied until complete reepithelialization of the cornea was achieved. If necessary, artificial tears and topical steroids (fluorometholone) were prescribed.

Follow-up Evaluation

Follow-up examinations were performed daily until complete reepithelialization. Subsequent examinations were at 1, 6, and 12 months and then annually. At each examination, refraction, best corrected visual acuity (BCVA) with glasses or with contact lenses, corneal topography, central corneal thickness (CCT), and intraocular pressure (IOP) were recorded.

Statistical Analysis

To quantify the crosslinking effect, the maximum K value of the apex, maximum and minimum K values in 3.0 mm zone topography, astigmatism, and BCVA were recorded. The changes were estimated by subtracting each parameter at the respective follow-up examination minus the day of crosslinking. Statistical evaluation was performed by analysis of variance (ANOVA) using SPSS software (version 12.5, SPSS, Inc.).

RESULTS

Two hundred forty-one eyes of 130 patients with a mean age of 30.04 years \pm 10.46 (SD) were included in the study. The mean follow-up was 26.7 \pm 16.2 months (range 12 months to 6 years). Preoperatively, the mean K value of the apex was 62.6 \pm 12.7 D, the mean maximum K value was 53.7 \pm 7.5 D, the mean astigmatism was 6.5 \pm 4.4 D, and the mean BCVA was 0.39 \pm 0.31 logMAR.

The improvements in BCVA, astigmatism, and K values were statistically significant after the first year postoperatively and remained stable for the remainder of the follow-up (Table 1 and Figures 1 to 3). One year after the crosslinking treatment, the BCVA improved at least 1 line in 53% of 142 eyes ($P < .01$) and remained stable in 20% of eyes. Astigmatism decreased by a mean of 0.93 D in 50% of eyes ($P < .01$) and remained stable (within ± 0.50 D) in 36% of eyes. The K value of the apex decreased by a mean of 2.68 D in 62% of eyes ($P < .01$) and remained stable in 17% (within ± 0.50 D). The maximum K value decreased by a mean of 1.46 D ($P < .01$) in 56% of eyes and remained stable (within ± 0.50 D) in 30% of eyes. The minimum decrease in astigmatism, the K value of the apex, and the maximum K value was 0.50 D.

Table 1. Mean change in recorded values after crosslinking.

Follow-up (y)	Mean \pm SD (%)*			
	Kmax Apex (D)	Kmax (D)	Astigmatism (D)	Visual Acuity (LogMAR)
1 (n = 142)	-2.68 \pm 7.61 (78.8)	-1.46 \pm 3.76 (85.9)	-0.93 \pm 3.67 (85.6)	-0.08 \pm 0.24 (73.1)
2 (n = 66)	-2.21 \pm 5.92 (79.3)	-1.91 \pm 4.36 (89.4)	-1.20 \pm 3.87 (84.8)	-0.09 \pm 0.24 (81.0)
3 (n = 33)	-4.84 \pm 7.47 (80)	-2.57 \pm 3.71 (67.2)	-1.45 \pm 3.05 (68.2)	-0.15 \pm 0.18 (87.1)
4 (n = 13)	-6.87 \pm 8.32 (84.6)	-2.66 \pm 2.85 (85.6)	-1.49 \pm 1.79 (85.6)	-0.18 \pm 0.11 (91.7)
5 (n = 5)	-1.41 \pm 4.56	-2.47 \pm 2.18	-1.47 \pm 3.39	-0.13 \pm 0.29
6 (n = 5)	-2.95 \pm 2.35	-2.44 \pm 2.02	-0.90 \pm 1.60	-0.18 \pm 0.06

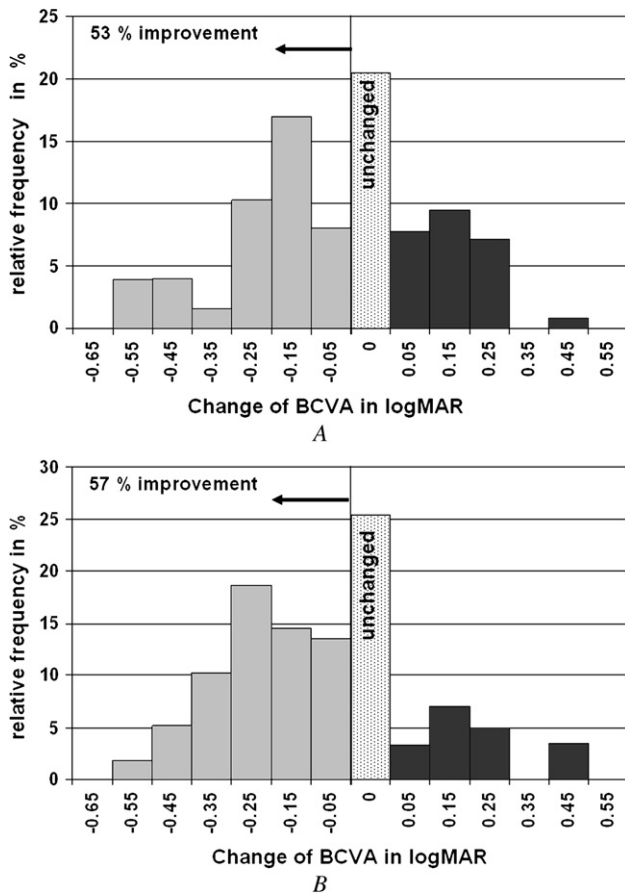
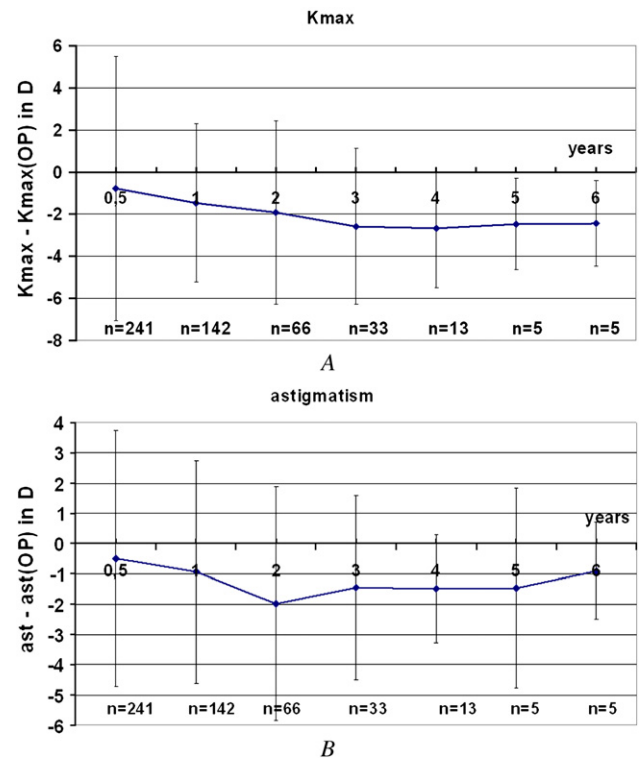
Kmax = maximum keratometry; n = number of examined eyes

*Percentage of the incidence of stable and improved parameters combined

An evaluation of 66 eyes in which stable parameters were recorded and the preoperative values on the day of treatment were compared with postoperative values of the second-year examination showed that BCVA improved at least 1 line in 57% of eyes and remained stable in 24% of eyes ($P < .01$). Astigmatism decreased by a mean of 1.20 D in 43% of eyes ($P < .01$) and remained stable (within ± 0.50 D) in 42% of eyes. The

K value of the apex decreased by a mean of 2.21 D in 60% of eyes ($P < .01$) and remained stable (within ± 0.50 D) in 19% of eyes. The maximum K value decreased by a mean of 1.91 D in 54% of eyes ($P < .01$) and remained stable (within ± 0.50 D) in 35% of eyes (Table 1 and Figures 1 to 3). The minimum decrease in astigmatism, the K value of the apex, and the maximum K value was 0.50 D.

Three years after the treatment, 33 eyes were examined. The BCVA improved at least 1 line in 58% of eyes and remained stable in 29% of eyes ($P < .01$). Astigmatism decreased by a mean of 1.45 D in 54% of eyes

**Figure 1.** A: Change in BCVA. After 1 year (n = 142). B: After 2 years (n = 66). Improvement means a gain of at least 1 line of BCVA.**Figure 2.** A: Change in maximum keratometry B: Change in astigmatism (ast) in the central 3.0 mm zone over the 6-year follow-up (mean \pm standard deviation) (Kmax = maximum keratometry).

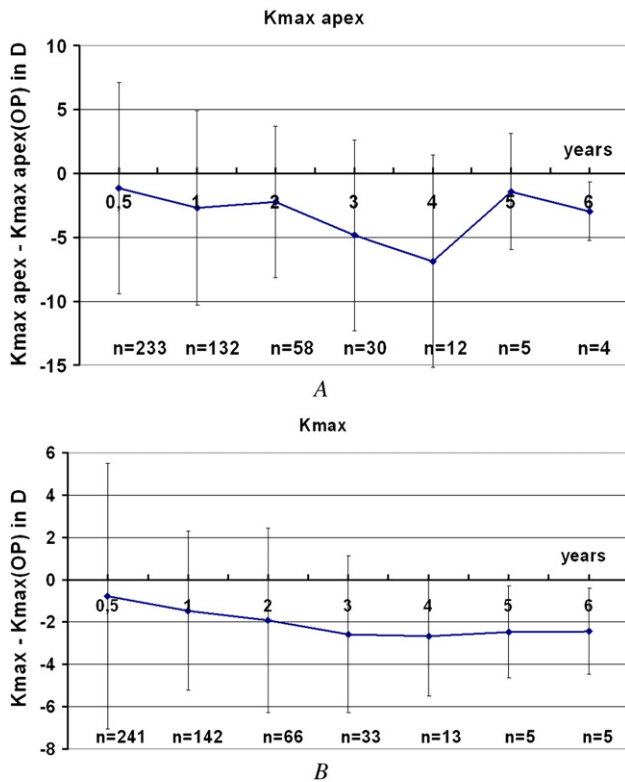


Figure 3. A: Change in K value of the apex (D). B: Change in maximum K value (Kmax) in central 3.0 mm zone over the 6-year follow-up (mean \pm standard deviation).

($P < .01$) and remained stable (within ± 0.50 D) in 14% of eyes. The K value of the apex decreased by a mean of 4.84 D in 78% of eyes ($P < .01$) and remained stable (within ± 0.50 D) in 2% of eyes. The maximum K value decreased by a mean of 2.57 D in 58% of eyes ($P < .01$) and remained stable (within ± 0.50 D) in 9% of eyes (Table 1 and Figures 2 to 4). The minimum decrease in astigmatism, the K value of the apex, and the maximum K value was 0.50 D.

In assessing the values of the subsequent years, the decreasing number of patients must be taken into consideration. Nevertheless, stabilization can be assumed (Table 1 and Figures 2 to 4).

There was no significant change in measured IOP (mean IOP_{first year} - mean IOP_{preoperative} = 0.2 ± 1.4 mm Hg after first year; mean IOP_{second year} - IOP_{preoperative} = -0.3 ± 1.4 mm Hg after second year) ($P > .05$). The mean change in CCT was -2 ± 12 μ m after the first year ($P > .05$) and 21 ± 31 μ m after the second year ($P < .05$).

Two patients (aged 21 and 27 years) came in for follow-up at 18 months and 21 months, respectively (after a period of stable status for several months). Both patients had neurodermatitis. The examination revealed progression of the keratoconus and worsening of the neurodermatitis. At that time, the patients were

on intensive systemic therapy for the background disease. Because of the direct correlation between the deterioration of the eye and the skin findings, the decision was made to repeat the crosslinking procedure in both cases.

Side effects such as endothelial damage or cataract were not expected in view of the results and recommendations of earlier studies (minimum corneal thickness 400 μ m).

DISCUSSION

Our study included a larger cohort and longer follow-up time than comparable studies reported to date. The number of patients in our cohort decreased with longer follow-up time because the study was longitudinal with consecutive recruitment. In a pilot study of 16 of 23 eyes 3 months to 4 years after crosslinking, Wollensak et al.²⁴ found a mean reduction in steepening of 2.01 D. Caporossi et al.²⁵ report a mean decrease in steepening of 2.10 D in a 10-patient cohort with a maximum follow-up of 6 months after crosslinking.

Our long-term retrospective study confirmed that collagen crosslinking is an effective therapeutical option for progressing keratoconus. Only 2 patients with acute exacerbation of neurodermatitis showed progression of keratoconus and therefore had repeat crosslinking. This finding agrees with an observation by Krumeich et al.,²⁶ who describe destabilization of the cornea and a tendency toward corneal melting after transplantation in patients with neurodermatitis.

The improvement in vision after crosslinking is caused by a decrease in astigmatism and corneal curvature as well as by topographical homogenization of the cornea as a result of the increased rigidity in the crosslinked cornea. In addition, the fitting of contact lenses is improved.

The increase in CCT after the second year should be studied further with optical pachymetry because it is suspected that the velocity of the ultrasound is changed due to structure modification (G. Karp, MD, D. Reinstein, MD, "VHF Ultrasound Eye Scanner Changes After Corneal Crosslinking," presented at the 3rd Corneal Cross Linking Congress, Zurich, Switzerland, December 2007). On the other hand, optical pachymetry also has intrinsic assumptions, one of which is tissue refractive index, which is expected to change in the area of the demarcation line as observed by Seiler and Hafezi.²⁷

Because of the convincing positive results in the first clinical study of collagen crosslinking,²⁴ comparison with a control group was ethically unacceptable. This is especially true in light of the Collaborative Longitudinal Evaluation of Keratoconus Study,^{22,28-30} which found a significant decline in vision within 8

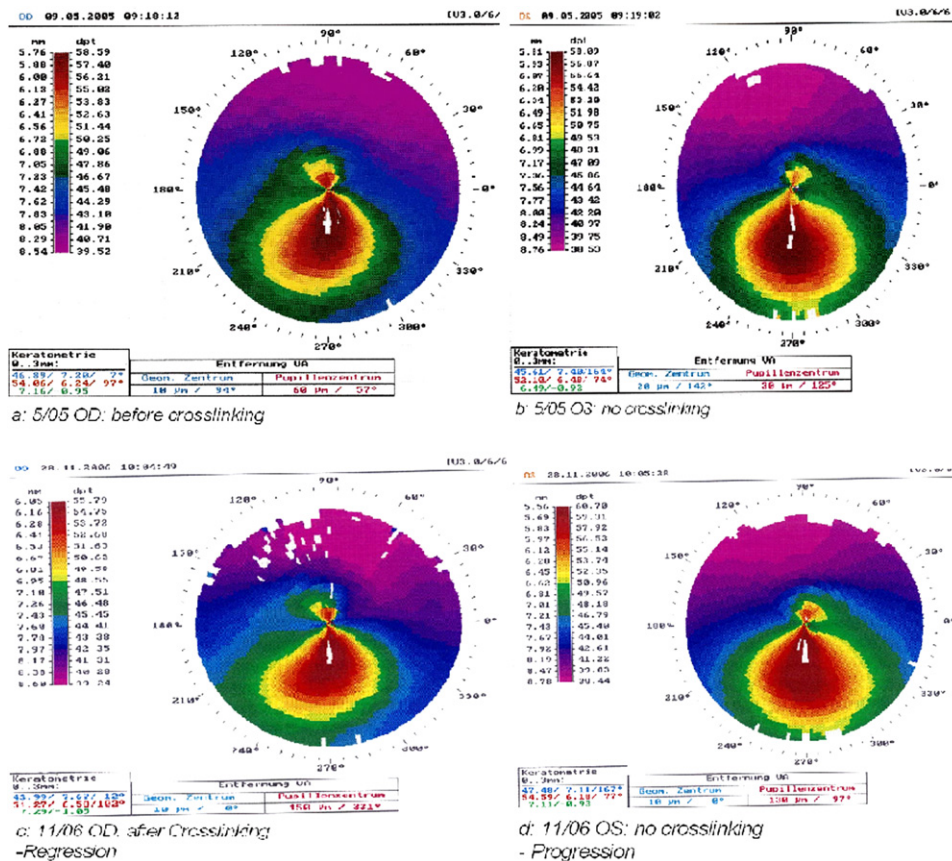


Figure 4. Corneal topography of a patient who had corneal crosslinking in the right eye; the left eye was not treated. A: Right eye on the day of crosslinking (BCVA 20/25). B: Left eye (BCVA 20/25) on the day of crosslinking. C: Right eye 18 months after crosslinking (reduction in steepening 2.80 D; BCVA 20/25). D: Left eye without crosslinking shows progression of keratoconus (increase in steepening of 2.61 D in 18 months; BCVA 20/50).

years, an increase in astigmatism and corneal curvature, subepithelial scarring, and corneal thinning in untreated keratoconic corneas.

Currently available conservative and surgical therapeutic options such as glasses, contact lenses, intracorneal rings, epikeratoplasty, thermal keratoplasty, and lamellar keratoplasty can temporarily correct the refractive effect but do not stop the progression of keratoconus. In the long term, perforating keratoplasty is often the only choice, although potential intraoperative and postoperative complications (eg, rejection, transplant failure, secondary cataract, secondary glaucoma, recurrence of keratoconus in the transplanted cornea) limit good long-term results.

By increasing the biomechanical stability of the cornea using riboflavin- and UVA-induced collagen crosslinking, it is possible to stop the progression of keratoconus and therefore avoid the need for keratoplasty. In addition to clinical advantages, there are enormous economical and psychosocial benefits. Crosslinking is a practical outpatient service and is a minimally invasive, cost-effective treatment with minimal stress for patients. In contrast, keratoplasty is surgically difficult, expensive, and time consuming; it has many risks despite its good reproducibility. Patients often require intensive topical postoperative treatment and frequent visits to the ophthalmologist

for many years. Furthermore, keratoplasty confers considerable restrictions in professional and private daily life.

At present keratoconus, is not curable. However, crosslinking can stop its progression. Thus, it is important to crosslink corneas with progressive keratoconus as early as possible. In the future, we may be able to further improve vision by combining the crosslinking procedure with procedures such as intracorneal ring implantation,³¹ topography-guided photorefractive keratectomy, and thermal keratoplasty, an area that is under clinical research (Wong JJ, et al. IOVS 2006; 47:ARVO E-Abstract 557).

REFERENCES

1. Pouliquen Y. Keratoconus; the Dooyne Lecture. *Eye* 1987; 1:1–14
2. Jiménez JLO, Jurado JCG, Rodriguez FJB, Laborda DS. Keratoconus: age of onset and natural history. *Optom Vis Sci* 1997; 74:147–151
3. Kymes SM, Walline JJ, Zadnik K, Gordon MO. Quality of life in keratoconus; the Collaborative Longitudinal Evaluation of Keratoconus (CLEK) Study Group. *Am J Ophthalmol* 2004; 138:527–535
4. Maeno A, Naor J, Lee HM, et al. Three decades of corneal transplantation: indications and patient characteristics. *Cornea* 2000; 19:7–11
5. Funderburgh JL, Panjwani N, Conrad GW, Baum J. Altered keratan sulfate epitopes in keratoconus. *Invest Ophthalmol Vis Sci* 1989; 30:2278–2281. Available at: <http://www.iovs.org/cgi/reprint/30/10/2278>. Accessed January 21, 2008

6. Rehany U, Lahav M, Shoshan S. Collagenolytic activity in keratoconus. *Ann Ophthalmol* 1982; 14:751–754
7. Sawaguchi S, Yue BYJT, Chang I, et al. Proteoglycan molecules in keratoconus corneas. *Invest Ophthalmol Vis Sci* 1991; 32:1846–1853. Available at: <http://www.iovs.org/cgi/reprint/32/6/1846>. Accessed January 21, 2008
8. Wollensak J, Buddecke E. Biochemical studies on human corneal proteoglycans—a comparison of normal and keratoconic eyes. *Graefes Arch Clin Exp Ophthalmol* 1990; 228:517–523
9. Kao WW-Y, Vergnes J-P, Ebert J, et al. Increased collagenase and gelatinase activities in keratoconus. *Biochem Biophys Res Commun* 1982; 107:929–936
10. Sawaguchi S, Yue BYJT, Sugar J, Gilboy J. Lysosomal enzyme abnormalities in keratoconus. *Arch Ophthalmol* 1989; 107:1507–1510
11. Zhou L, Sawaguchi S, Twining SS, et al. Expression of degradative enzymes and protease inhibitors in corneas with keratoconus. *Invest Ophthalmol Vis Sci* 1998; 39:1117–1124. Available at: <http://www.iovs.org/cgi/reprint/39/7/1117>. Accessed January 21, 2008
12. Kenney MC, Nesburn AB, Burgeson RE, et al. Abnormalities of the extracellular matrix in keratoconus corneas. *Cornea* 1997; 16:345–351
13. Daxer A, Fratzl P. Collagen fibril orientation in the human corneal stroma and its implication in keratoconus. *Invest Ophthalmol Vis Sci* 1997; 38:121–129. Available at: <http://www.iovs.org/cgi/reprint/38/1/121>. Accessed January 21, 2008
14. Meek KM, Tuft SJ, Huang Y, et al. Changes in collagen orientation and distribution in keratoconus corneas. *Invest Ophthalmol Vis Sci* 2005; 46:1948–1956. Available at: <http://www.iovs.org/cgi/reprint/46/6/1948>. Accessed January 21, 2008
15. Radner W, Zehetmayer M, Skorpik C, Mallinger R. Zur Anordnung der kollagenen Lamellen beim Keratokonus. [SEM findings in keratoconus]. *Spektrum Augenheilkd* 1996; 10:156–160
16. Wollensak G. Crosslinking treatment of progressive keratoconus: new hope. *Curr Opin Ophthalmol* 2006; 17:356–360
17. Spoerl E, Wollensak G, Seiler T. Increased resistance of cross-linked cornea against enzymatic digestion. *Curr Eye Res* 2004; 29:35–40
18. Spörl E, Schreiber J, Hellmund K, et al. Untersuchungen zur Verfestigung der Hornhaut am Kaninchen. [Cross-linking effects in the cornea of rabbits]. *Ophthalmologe* 2000; 97:203–206
19. Spoerl E, Huhle M, Seiler T. Induction of cross-links in corneal tissue. *Exp Eye Res* 1998; 66:97–103
20. Spörl E, Huhle M, Kasper M, Seiler T. Erhöhung der Festigkeit der Hornhaut durch Vernetzung. [Artificial stiffening of the cornea by induction of intrastromal cross-links]. *Ophthalmologe* 1997; 94:902–906
21. Kohlhaas M, Spoerl E, Schilde T, et al. Biomechanical evidence of the distribution of cross-links in corneas treated with riboflavin and ultraviolet A light. *J Cataract Refract Surg* 2006; 32:279–283
22. Suzuki M, Amano S, Honda N, et al. Longitudinal changes in corneal irregular astigmatism and visual acuity in eyes with keratoconus. *Jpn J Ophthalmol* 2007; 51:265–269
23. Spoerl E, Mrochen M, Sliney D, et al. Safety of UVA-riboflavin cross-linking of the cornea. *Cornea* 2007; 26:385–389
24. Wollensak G, Spoerl E, Seiler T. Riboflavin/ultraviolet-A-induced collagen crosslinking for the treatment of keratoconus. *Am J Ophthalmol* 2003; 135:620–627
25. Caporossi A, Baiocchi S, Mazzotta C, et al. Parasurgical therapy for keratoconus by riboflavin-ultraviolet type A rays induced cross-linking of corneal collagen; preliminary refractive results in an Italian study. *J Cataract Refract Surg* 2006; 32:837–845
26. Krumeich JH, Daniel J, Knülle A. Live-epikeratophakia for keratoconus. *J Cataract Refract Surg* 1998; 24:456–463
27. Seiler T, Hafezi F. Corneal cross-linking-induced stromal demarcation line. *Cornea* 2006; 25:1057–1059
28. Barr JT, Wilson BS, Gordon MO, et al. Estimation of the incidence and factors predictive of corneal scarring in the Collaborative Longitudinal Evaluation of keratoconus (CLEK) Study; the CLEK Study Group. *Cornea* 2005; 25:16–25
29. Davis LJ, Schechtman KB, Wilson BS, et al. Longitudinal changes in visual acuity in keratoconus; the Collaborative Longitudinal Evaluation of Keratoconus (CLEK) Study Group. *Invest Ophthalmol Vis Sci* 2006; 47:489–500. Available at: <http://www.iovs.org/cgi/reprint/47/2/489>. Accessed January 21, 2008
30. McMahon TT, Edrington TB, Szczołka-Flynn L, et al. Longitudinal changes in corneal curvature in keratoconus. *Cornea* 2006; 25:296–305
31. Chan CCK, Sharma M, Boxer Wachler BS. Effect of inferior-segment Intacs with and without C3-R on keratoconus. *J Cataract Refract Surg* 2007; 33:75–80



First author:

Frederik Raiskup-Wolf, MD

Department of Ophthalmology, C.G. Carus University Hospital, Dresden, Germany